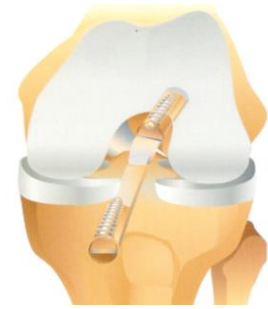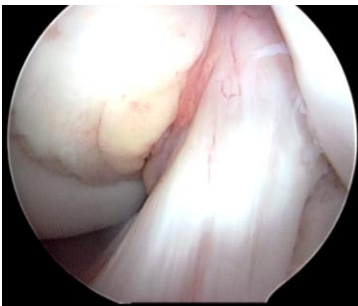


ACL Injuries

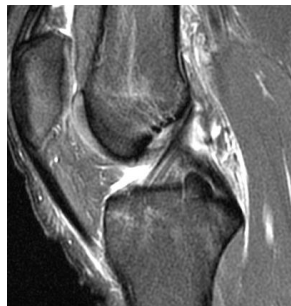Marc S. Fineberg MD



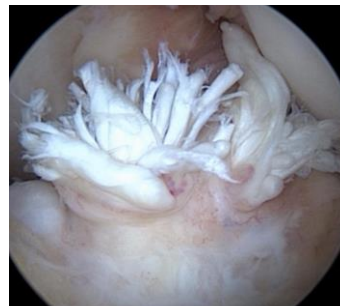The anterior cruciate ligament (ACL) is the primary stabilizer of the knee. It is a strong fibrous band of tissue at the center of the knee joint which holds the thigh bone (femur) and shin bone (tibia) together during active knee motion. It is typically torn when the knee twists abnormally, or is in a collision. The ACL injured athlete is at high-risk for knee instability, cartilage tears and progressive degeneration. An ACL tear will not spontaneously heal; it must be surgically “reconstructed”.



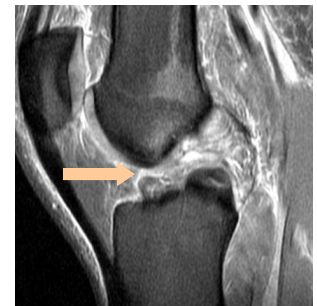Normal ACL



MRI of Normal ACL



Torn ACL



MRI of Torn ACL

The majority of ACL injuries are associated with sports participation, with an average age of 26 years. Most ACL injuries occur within a 30-year age bracket (15 to 45 years). In soccer, basketball, and volleyball, the rate of ACL injury is several times higher in women than in men. The reason for higher injury rates in female athletes remains elusive but is likely multifactorial.

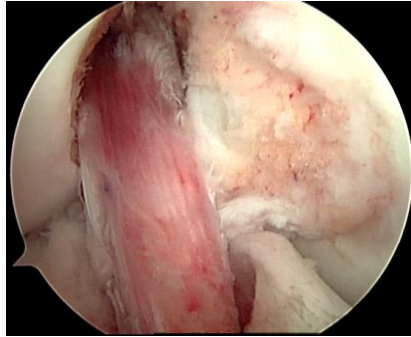
While much progress has been made in the diagnosis and treatment of ACL tears, little information exists regarding the prevention of this costly injury. Several factors have been the focus of interest for ACL researchers. Risk factors for ACL injuries can be divided into anatomic, environmental, hormonal, biomechanical, and neuromuscular factors.

Success rates in ACL surgery vary but may be up to 90%. Important factors include graft selection, fixation, tunnel placement and post-operative rehabilitation.

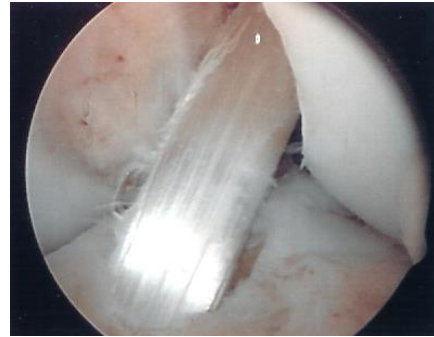
The torn ends of the ACL can not be simply sewed together. The ACL is commonly replaced with a graft taken through an open incision on the front or medial (inner) side of the knee. The most common options are the mid-third bone-patella tendon-bone graft (B-PT-B) and the hamstring graft.

The major benefit of the B-PT-B graft is solid bone to bone fixation with interference screws which promotes rapid graft incorporation and allows for accelerated rehabilitation. Excellent results have been obtained with this graft. The downside of the B-PT-B graft is the more invasive nature of harvesting bone plugs. There is also a consensus that B-PT-B grafts have an increased incidence of residual anterior knee pain, localized sensory loss, and discomfort with kneeling. A rare patellar fracture can lead to additional surgery.

An excellent alternative to the B-PT-B graft is the hamstring graft. As soft-tissue fixation techniques have improved, hamstring tendon grafts are gaining popularity. Patient satisfaction and clinical results have consistently been on par with the B-PT-B grafts.



Bone Patellar Tendon Bone Graft



Hamstring Graft

Other graft options include the quadriceps tendon and allografts (cadaver grafts). Allografts are appealing in that there is no need to take a graft from the patient resulting in less operative time and a smaller incision. The limited availability, increased cost, potential for disease transmission, and less promising clinical results have prevented their widespread use as the primary option for ACL replacement. Currently, allografts are most useful for multiple ligament reconstructions or revision cases.

Regardless of the graft option, placement of the graft is performed under arthroscopic visualization. The key to the procedure is accurate bone tunnel placement with solid graft fixation. Tunnel placement is aided by mechanical guides positioned according to specific anatomic landmarks. In spite of these guides, inaccurate tunnel placement remains a leading cause of surgical failure. Inaccurate tunnel placement can cause the graft to be too loose or too tight with resultant recurrent instability or loss of motion.

ACL surgery is usually performed on an outpatient basis under general anesthesia. The procedure takes approximately one hour. Additional time may be required to address any cartilage injuries. A knee immobilizer and crutches are used for two to three weeks. Physical therapy is started immediately with a focus on regaining motion and gentle strengthening. An effective rehabilitation program should allow for normal walking by one month and light jogging by three months. Return to jumping and pivoting activities occurs at five to six months after surgery.

Advances in ACL surgery have focused on more precise tunnel placement and more accurate recreation of normal ACL anatomy.